

⇒ Case Report



Primary Rectal Teratoma Presenting as an Irritable Bowel-like Syndrome: A Case Report

Mohammad Reza Pashaei¹, Amir Tahavori^{1*}¹Department of Internal Medicine, School of Medicine, Urmia University of Medical Sciences, Urmia, Iran**Abstract**

Background: Teratoma is a tumor comprised of three germinal layers classified as mature or immature in most cases. Most mature solid teratomas are benign but may turn malignant; therefore, complete resection is advised in these cases. They usually occur in women. Primary rectal teratomas are infrequent, and only a few cases have been described in the literature. Teratomas are the most common cystic that rise in the ovary, testicle, and retroperitoneum. They can also be solid and are better known as dermoid cysts.

Case Presentation: We report a 34-year-old woman who were presented with intermittent constipation and diarrhea in Urmia Imam Khomeini Hospital in January 2020. After examination, a solid intra-rectal teratoma occurring mainly in the rectum was detected in this case. The patient underwent segmental colectomy and histology, which revealed squamous epithelium, fat cells, hair follicles, cartilaginous material, and granuloma suggestive of mature teratoma.

Conclusion: The present case was a solid primary rectal teratoma, an uncommon disease with many misdiagnoses that can be differentiated from other diseases. In this case report, it is differentiated from irritable bowel syndrome (IBS).

Keywords: Rectum, Teratoma, Irritable bowel syndrome

***Correspondence to**

Amir Tahavori,
Tel: +98 9120974067,
Email: tahavori69@gmail.
com



Received June 19, 2021, Accepted: October 30, 2021, Published Online: August 16, 2022

Background

Teratoma is the most common ovarian tumor and may less frequently originate in the gastrointestinal tract (1). Most teratomas are cystic and composed of mature differentiated elements (2). Rectal teratoma is highly rare, and only a few cases have previously been reported in this regard in the literature. In this study, we report a case of primary rectal teratoma presented with intermittent diarrhea and constipation with abdominal pain, which is rare and has not been reported so far.

Case Presentation

A 34-year-old Iranian woman was presented with a five-month history of intermittent non-bloody diarrhea, constipation, and mild abdominal pain in Urmia Imam Khomeini Hospital in January 2020. She also complained of weight loss of about 2 kg over the last six months. Six years ago, the patient was diagnosed with a known case of Mediterranean fever which was under the treatment of colchicine. The patient had infertility for three years and underwent various tests for its treatment one year ago. Due to ascites and abdominal pain, the patient was suspected of having peritoneal tuberculosis and underwent diagnostic laparoscopy, but no acid-fast bacilli biopsy was reported for her.

Her family history was noncontributory. Three months before admission to the hospital, she was examined and diagnosed with irritable bowel syndrome (IBS) and

received drug treatment. The frequency of abdominal pain decreased after the initial treatment. However, the patient's pain gradually increased after one month, and she was re-examined and hospitalized with the same clinical presentation. According to physical examinations, she was fully conscious with a 100/70 mmHg blood pressure, a pulse rate of 90 beats/min, and a temperature of 37.6°C (Table 1). Abdominal examination showed slight tenderness of the lower abdomen. Based on digital rectal examinations, in addition to skin tags, the findings represented mild perianal erythema.

An ultrasound of the abdomen and pelvic revealed an echogenic mass with internal fluid on the right ovary, (78 * 48 mm) and echogenic internal material extended up to the left ovary. Another hypoechoic mass (98 * 37) mm including multiple collections with echo-free cysts with echogenic internal septate was detected on the right side of the pelvic in the omentum and intraperitoneal.

Abdominopelvic magnetic resonance imaging (MRI) demonstrated two cystic lesions located in the anterior uterus with a few thin septa suggestive of peritoneal inclusion cysts with some loculated fluid areas in the lower abdomen in the inter loop space. A cystic lesion (50*27*24 mm) was observed in the left adnexa (probably originated from the ovary) with an 8*5 mm T1 hyperintense component (probably, it was hemorrhage), showing rectal wall thickening. There was also an intramural-like area (33*18*14 mm) in the posterior

Table 1. Laboratory Finding of the Patient

Test	Value
Hematologic Tests	
White blood cell count	9600/mm ³
Neutrophil	82%
Lymphocyte	16%
Monocyte	2%
ESR	38 mm/h
Hemoglobin	11.5 gr/dL
CRP	25 mg/L (normal up to 10 mg/L)
Platelets	165000/mm ³
Blood culture	Negative
Biochemistry Tests	
Total protein	5.5 g/dL
Albumin	3.2 g/dL
Indirect bilirubin	0.5mg/dL
Blood sugar	80 mg/dL
BUN	32 mg/dL
Creatinine	1.2 mg/dL
Amylase	63 IU/L
Aspartate transaminase	22 IU/L
Alanine transaminase	28 IU/L
Alkaline phosphatase	159 IU/L
Direct bilirubin	0.4 mg/dL
Total bilirubin	0.9 mg/dL
Na	138 mEq/L
K	3.9 mEq/L
Ca	9.4 mg/dL
P	5 mg/dL

Abbreviations: ESR, erythrocyte sedimentation rate; CRP, C-reactive protein; BUN, blood urea nitrogen; Na, sodium blood test; K, potassium blood test; CA, cancer antigen.

rectal wall with a 10-12 cm distance from the anal verge, containing air with intraluminal communication and probably attached to the left adnexal mass.

The patient underwent endoscopic ultrasonography that represented a large heterogeneous mass lesion (88*45 mm) above the uterus with the areas of cysts degeneration and calcification invaded into the rectal wall and extended to the lumen resembling an exophytic pattern bulging from the serosa (Figure 1).

On colonoscopy, a pedunculated polypoid (4*5 cm) lesion with a distance of 12 cm from the anal verge was detected that contained a tooth-like structure, and a few hairs were projected from the surface of the lesion (Figure 2).

Due to invasion in the mass and its large size, endoscopic tumor resection was extremely difficult; then, a surgical plan was inserted, and the patient underwent laparotomy, which revealed a mass in the rectum and an adhesion band with mesenteric granuloma. Segmental colectomy was performed, making colostomy after

the release of abundant adhesion. The patient did not have any postoperative complications. Thus, she was discharged from the hospital a few days after the surgery and obtained adequate gas and feces control.

The histological examination of mesocolon mass showed squamous epithelium, granulomatous inflammation, hair follicles, cartilaginous material, and columnar lining of the glandular structures suggestive of mature teratoma. After six months, the patient underwent computerized tomography (CT) scan for evaluation; no obvious intrapelvic abnormality was revealed, and side-to-side anastomosis was made after this time.

Discussion

Mature teratoma is a three-layered germ cell tumor commonly found in the ovary, testes, or mediastinum (3). Due to the lack of germ cells in the gastrointestinal tract, teratoma occurs less commonly in the digestive tract (4). It is believed that primary rectal teratoma only occurs when germ cell aberrantly enters the digestive tract. Primary rectal teratomas are scarce, and only a few cases have been described in the literature (5). Only 54 cases were reported in the world, and four cases have been published in Korea (6, 7). Rectal teratoma is more common in women, with only one case reported in men. Teratoma is highly suspected when there is hair on the

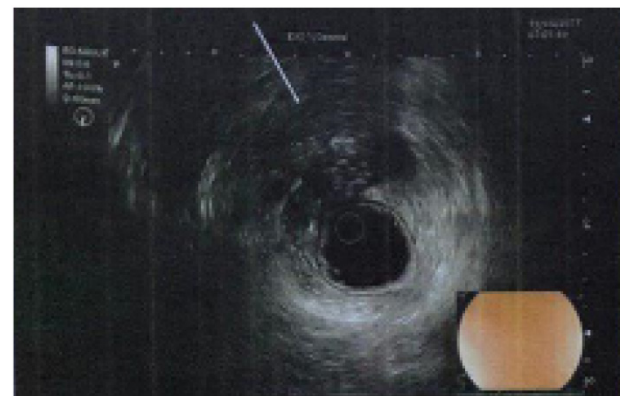

Figure 1. Endoscopic ultrasound that revealed a large heterogeneous mass lesion

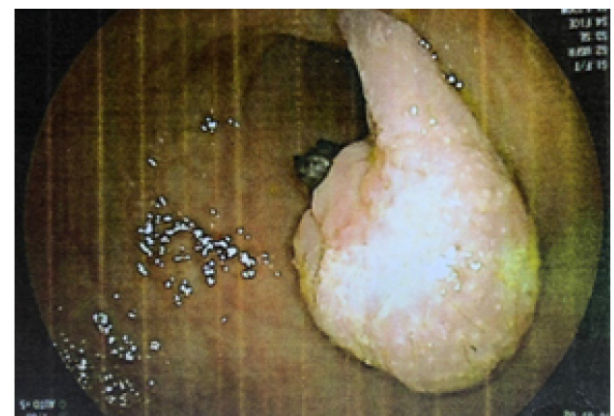


Figure 2. Pedunculated polypoid lesion in colonoscopy

surface of the tumor during colonoscopy (8, 9). In this reported case, hairs were found on the out layer of the mass, which raised the suspicion of a rectum teratoma. The majority of teratoma is polypoid-shaped protruding into the rectal lumen similar to the present case. Many patients were presented with a prolapse of the tumor or hair, pain on defecation, and many had bloody stool (10). In one related case in the literature, the presenting complaint was only constipation (11). However, our case was presented with intermittent constipation and diarrhea with abdominal pain marked as IBS on two outpatient visits. The most commonplace of tumor development was the anterior wall of the rectum. However, a few cases reported that the tumor arose from the posterior and occasionally lateral wall (12). *Endoscopic ultrasonography* plays an essential role in treating rectal lesions.

It is often difficult to distinguish between primary and secondary rectal teratomas. The presence of a well-defined pedicle may demonstrate that its origin is from a rectum, and a primary rectal teratoma is completely covered by squamous epithelium. In contrast, ovarian teratoma has squamous epithelium as one component in the form of cysts inside the tumor. After six months, the CT scan represented that both of the ovaries were free of any lesions.

In summary, we presented a case of primary mature teratoma of the rectum, which was found to be similar to IBS and was successfully treated with surgical resection. It is commonly benign but may turn malignant.

Table 1 presents the results of the patient's physical examination, along with hematologic and biochemistry tests.

Acknowledgments

The authors would like to express their gratitude to the Clinical Research Development Unit of Imam Khomeini Hospital, Urmia University of Medical Sciences for English editing.

Authors' Contribution

MRP was responsible for designing the review protocol, writing the protocol and report, conducting the search, screening potentially eligible studies, extracting. AR contributed to writing the report, extracting and analyzing data, interpreting results, and creating a summary of the findings of the table. Both authors discussed the results and contributed to the final manuscript.

Disclaimer

This is a case report paper, and hence it reports an important case of illness. This paper represents the opinions of the authors and is the product of professional research. It is not meant to represent

the official position of any staff members. Any errors are the fault of the authors.

Ethical Approval

Written informed consent for the publication of the article and any associated images were obtained from the patient.

Funding/Support

There is no source of any support for this paper.

References

1. Vang R, Gown AM, Zhao C, Barry TS, Isacson C, Richardson MS, et al. Ovarian mucinous tumors associated with mature cystic teratomas: morphologic and immunohistochemical analysis identifies a subset of potential teratomatous origin that shares features of lower gastrointestinal tract mucinous tumors more commonly encountered as secondary tumors in the ovary. *Am J Surg Pathol*. 2007;31(6):854-69. doi: [10.1097/PAS.0b013e31802efb45](https://doi.org/10.1097/PAS.0b013e31802efb45).
2. Sahin H, Abdullazade S, Sancı M. Mature cystic teratoma of the ovary: a cutting edge overview on imaging features. *Insights Imaging*. 2017;8(2):227-41. doi: [10.1007/s13244-016-0539-9](https://doi.org/10.1007/s13244-016-0539-9).
3. Kumar V, Abbas AK, Fausto N, Aster JC. *Robbins & Cotran Pathologic Basis of Disease*. 8th ed. Philadelphia, PA: Saunders; 2010.
4. Takao Y, Shimamoto C, Hazama K, Itakura H, Sasaki S, Umegaki E, et al. Primary rectal teratoma: EUS features and review of the literature. *Gastrointest Endosc*. 2000;51(3):353-5. doi: [10.1016/s0016-5107\(00\)70370-1](https://doi.org/10.1016/s0016-5107(00)70370-1).
5. Sakurai Y, Uruguchi T, Imazu H, Hasegawa S, Matsubara T, Ochiai M, et al. Submucosal dermoid cyst of the rectum: report of a case. *Surg Today*. 2000;30(2):195-8. doi: [10.1007/s005950050043](https://doi.org/10.1007/s005950050043).
6. Park J, Byeon JS, Jo JH, Kim KJ, Ye BD, Myung SJ, et al. Endoscopic polypectomy of primary rectal mature teratoma: a case report. *Korean J Gastrointest Endosc*. 2009;39(5):308-12.
7. Singh O, Gupta SS, Mathur RK. A rare case of primary solid intrarectal dermoid. *Saudi J Gastroenterol*. 2011;17(1):74-6. doi: [10.4103/1319-3767.74466](https://doi.org/10.4103/1319-3767.74466).
8. Green JB, Timmcke AE, Mitchell WT Jr. Endoscopic resection of primary rectal teratoma. *Am Surg*. 1993;59(4):270-2.
9. Oh SY, Song SC, Lee KJ, Kim YB, Suh KW. A case of a rectal teratoma. *J Korean Soc Coloproctol*. 2007;23(2):129-31.
10. Jona JZ. Congenital anorectal teratoma: report of a case. *J Pediatr Surg*. 1996;31(5):709-10. doi: [10.1016/s0022-3468\(96\)90682-x](https://doi.org/10.1016/s0022-3468(96)90682-x).
11. Yang Y, Wang X, Li Z, Xiang J, Chen Z. Identification of a mature cystic teratoma mimicking a presacral tumor by transsacral surgery in a young female: A case report. *Oncol Lett*. 2013;6(3):785-8. doi: [10.3892/ol.2013.1453](https://doi.org/10.3892/ol.2013.1453).
12. Aldridge MC, Boylston AW, Sim AJ. Dermoid cyst of the rectum. *Dis Colon Rectum*. 1983;26(5):333-4. doi: [10.1007/bf02561710](https://doi.org/10.1007/bf02561710).